



A Rare Case of Asymptomatic Mediastinal Thymolipoma-presenting as Opaque Hemithorax

**Rajoo Ramachandran¹, Udaya Bhaskarini Vakamudi^{1*}, Roy Santosham¹,
Periasamy Varadaraju Prithiviraj¹, Subramanian Ilanchezhian¹
and Thangavelu Periaswamy²**

¹Department of Radiology, Sri Ramachandra University, Porur, Chennai, Tamilnadu, India.

²Department of Cardiothoracic Surgery, Sri Ramachandra University, Porur, Chennai, Tamilnadu, India.

Author's contribution

This work was carried out in collaboration between all authors. Author RR designed the study, wrote the protocol, and wrote the first draft of the manuscript, author UBV managed the literature searches, author RS did the biopsy and analyses of the study performed, author PVP did the manuscript review, author SI managed the manuscript editing and author TP performed the surgery. All authors read and approved the final manuscript.

Article Information

DOI:10.9734/BJMMR/2015/19321

Editor(s):

(1) Anonymous.

Reviewers:

(1) Anonymous, Institute of Liver and Biliary Sciences, New Delhi, India.

(2) Alexander E Berezin, Internal Medicine Department, Zaporozhye Medical University, Zaporozhye, Ukraine.

Complete Peer review History: <http://sciencedomain.org/review-history/9978>

Case Study

Received 3rd June 2015
Accepted 17th June 2015
Published 29th June 2015

ABSTRACT

Aim: To describe the imaging features of a rare case of an asymptomatic thymolipoma presenting as opaque hemithorax. Thymolipoma is a rare benign neoplasm of the thymus which is composed of thymic elements and adipose tissue.

Presentation of Case: We present a case of opaque hemithorax in a 37 year old male following trauma to the chest. The patient had pain in the left side of the chest following a trauma and his physical examination showed tenderness in the left upper chest.

Discussion: Plain radiography was done which showed an opaque hemithorax. Computed tomography of the chest was done which revealed a large fat containing mass lesion occupying the entire right hemithorax.

Conclusion: To our knowledge there are only few cases of such unusual presentation of giant thymolipomas reported in English literature. The main purpose of this report is to discuss the rare presentation of a giant asymptomatic thymolipoma and the role of imaging in aiding the diagnosis.

*Corresponding author: Email: udayavakamudi@gmail.com;

Keywords: *Thymolipoma; mediastinum; computed tomography.*

1. INTRODUCTION

Thymolipoma is a rare benign tumor of anterior mediastinum which was first described by Lange in 1916 and further coined by Hall in 1949 [1,2]. Thymolipomas consists of elements of both mesodermal (fat) and endodermal (thymic epithelium) origin [3]. The imaging characteristics are those of fat and the thymic tissue appear as islands of soft tissue density within the fat [4]. Thymolipomas are soft and pliable tumors and accommodate themselves into the spaces between the lungs, heart, diaphragm and anterior mediastinum [5].

2. CASE PRESENTATION

A thirty seven year old male came with complaints of left side chest pain following trauma to the chest during bull fight. Initial physical examination showed mild tenderness in the upper chest on the left side. The patient had no specific complaint before the trauma. Chest radiography in frontal projection showed opaque right hemithorax with shift of trachea to the left side (Fig.1). The left hemithorax was unremarkable. All the blood investigations were unremarkable. Computed tomography of the thorax with contrast was done which showed a large non enhancing fat containing mass lesion (HU ranging from -71 to -102) of size 27 x 15.3 cm is seen in the right hemithorax causing

displacement of the trachea, oesophagus and the heart to the left side. The lesion is seen to extend into the anterior and posterior mediastinum with mild herniation into the contralateral hemithorax (Figs. 2a and 2b).

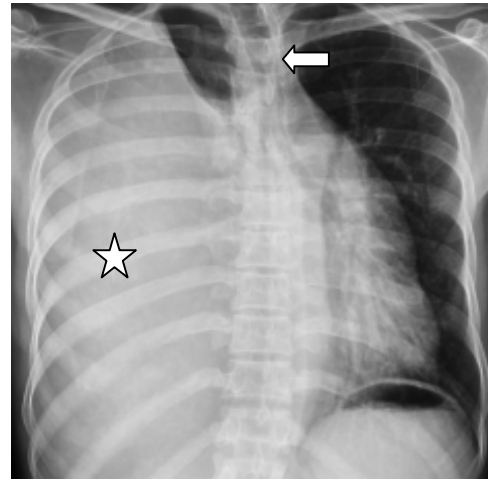


Fig. 1. 37-year old asymptomatic male diagnosed with mediastinal thymolipoma. Chest radiography frontal projection shows homogenous opacity (asterisk) involving the right hemi thorax with sparing of the apical segment of the right upper lobe. The trachea is mildly shifted to the left (left arrow)

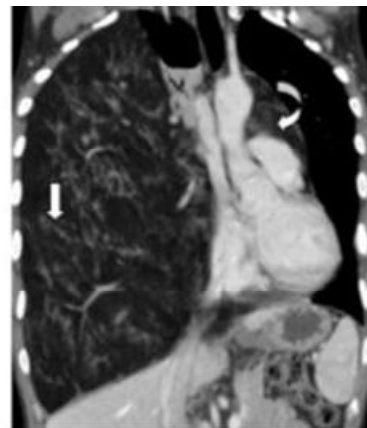
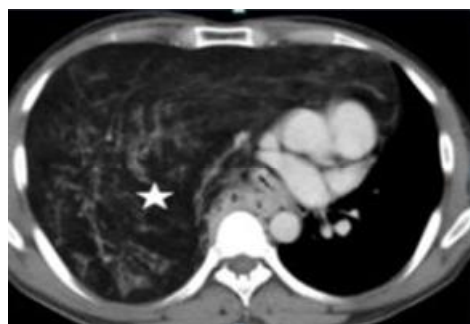


Fig. 2a and 2b. 37-year old asymptomatic male diagnosed with mediastinal thymolipoma. CT scan-Post contrast axial view and reformatted coronal view of the chest in mediastinal window shows a large non enhancing fat containing mass lesion(asterisk) occupying the right hemithorax with extension into the anterior and posterior mediastinum and mild herniation into the contralateral hemithorax (curved arrow).Streaks of non enhancing soft tissues are seen within the lesion which represents thymic tissue (down arrow).

No areas of calcification were noted within the mass lesion. No adjacent rib erosion/cortical breach noted. Few arterial branches from the aortic arch is seen to course within the mass lesion. Multiple veins are seen draining into the brachiocephalic vein. Flattening of the right hemi diaphragm seen. Based on the imaging findings we raised the possibility of mediastinal thymolipoma. Following which CT guided biopsy of the mass was done (Fig. 3) and sent for histopathological analysis. Histopathology showed mature adipocytes admixed with normal thymic tissue and hassal corpuscles suggesting thymic lipoma (Fig. 4). The patient underwent right posterolateral thoracotomy and a large fat containing mass weighing 2.7 kg was excised from the right hemithorax (Fig. 5). Post operative period was uneventful and the patient was discharged after 1 week.

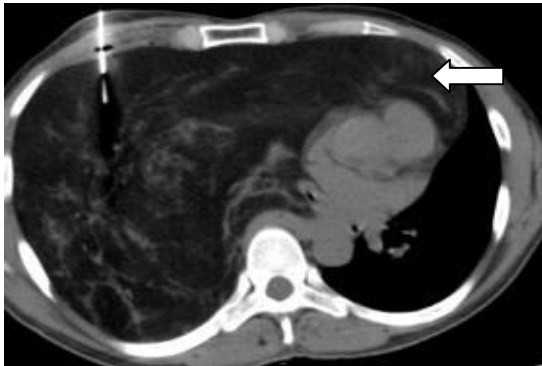

Fig. 3. 37-year old asymptomatic male diagnosed with mediastinal thymolipoma. CT guided biopsy of the fat containing mass. The needle is seen to be inside the fatty lesion (left arrow)

3. DISCUSSION

Thymolipomas are rare slow-growing mediastinal tumors constituting only 2–9% of all thymic neoplasm's. It is composed of mature adipose tissue with islands of benign thymic tissue interspersed. They are soft and pliable tumors and bend inferiorly as they enlarge [5]. They are said to slump onto the diaphragm, accommodating themselves in the spaces between the lungs, heart, diaphragm, or anterior mediastinum.

Thymolipomas are commonly seen between 3-56 years with a mean age of 22 years. The incidence of thymolipoma is roughly 0.12 per 100000 people per year [6]. No specific sex predilection.

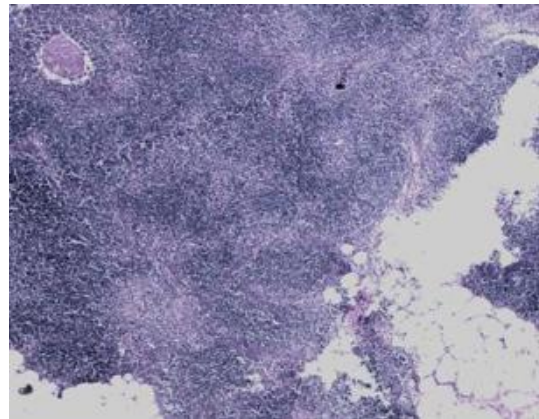


Fig. 4. 37-year old asymptomatic male diagnosed with mediastinal thymolipoma. Photomicrograph of hematoxylin and eosin (x 200) stained biopsy sample of the mediastinal mass shows mature adipocytes admixed with normal thymic tissue and hassal corpuscles suggesting thymic lipoma

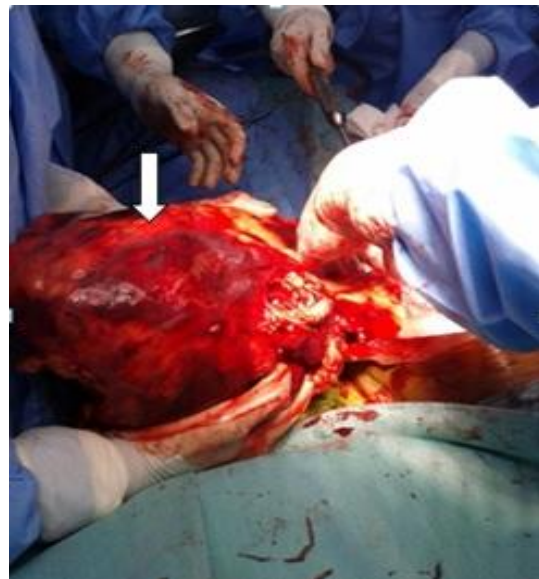

Fig. 5. 37-year old asymptomatic male diagnosed with mediastinal thymolipoma. Intra operative image showing a large thymolipoma (down arrow) being excised from the right hemithorax

These tumors are slow growing and usually asymptomatic. Sometimes the affected individual can present with respiratory tract infections and respiratory distress when the tumor grows to a larger size [7]. However if there is no symptoms the tumor can reach larger sizes before diagnosis as seen in our case [8,9,10].

Thymolipoma can be associated with other diseases; such as myasthenia gravis, systemic lupus erythematosus, red cell aplasia, hypogammaglobulinemia, graves' disease and cystic lymphangioma [8,9,10].

Microscopic examination shows normal adult adipose tissue with accumulation of lymphocytes and the characteristic scattered islands of Hassal's concentric corpuscles of thymic tissue [11].

Radiologically thymolipomas usually present as anterior mediastinal masses. They are seen to hang along one or both the sides of the pericardium and mould themselves into the adjacent mediastinum and diaphragm [4]. Thymolipomas are predominantly fat containing lesions and it is very difficult to identify them on chest radiography. They can mimic cardiomegaly, pericardial effusion or pericardial tumors [12].

On CT thymolipomas predominantly appear as a fat density lesion admixed with streaks of soft tissue representing thymic tissue [13,14].

As the thymolipomas consist of fat and soft tissue, the signals vary on each sequence which are as follows: On T1 sequence they appear hyper intense and the thymic soft tissue has intermediate signal. STIR shows fat suppression.

The differential diagnosis for fat containing mass lesion in the mediastinum include lipoma mediastinal lipomatosis, liposarcoma, teratoma, diaphragmatic hernias, extramedullary erythropoiesis, lipoid pneumonia, lipoblastoma and cardiac liposarcomas [15,16,17]. As mentioned above, thymolipomas are fat density lesions admixed with streaks of soft tissue. If the soft tissue show contrast enhancement the possibility of liposarcoma are to be considered.

Surgical resection of the thymolipoma is curative. No evidence of recurrence or metastasis has been reported.

4. CONCLUSION

Thymolipomas are unusual anterior mediastinal tumors accounting for about 5% of thymic tumors and are detected incidentally. Early detection should be the primary objective of the radiologist and the clinician to avoid complications related to pressure defects. Surgical resection is the

treatment of choice and recurrence of thymolipomas is uncommon.

CONSENT

All authors declare that written informed consent was obtained from the patient (or other approved parties) for publication of this case report and accompanying images.

ETHICAL APPROVAL

All authors hereby declare that all experiments have been examined and approved by the appropriate ethics committee and have therefore been performed in accordance with the ethical standards laid down in the 1964 Declaration of Helsinki.

COMPETING INTERESTS

Authors have declared that no competing interests exist.

REFERENCES

1. Lange I. Ueber ein Lipom des Thymus. Cited from Zentralbl Allg Pathol Anat. 1916;27: 97-100.
2. Hall GFM. A case of thymolipoma. Brit. J. Surg. 1949;36:321.
3. Moran CA, Rosado-de-Christenson M, Suster S. Thymolipoma: clinicopathologic review of 33 cases. Mod Pathol. 1995;8: 741-4.
4. Shirkhoda A, Chasen MH, Eftekhari F, Goldman AM, Decaro LF. MR imaging of mediastinal thymolipoma. J Comput Asst Tomogr. 1987;11:364-365.
5. Teplick JG, Nedwich A, Haskin ME. Roentgenographic features of thymolipoma. AJR. 1973;117:873-877.
6. Gamondes JP, Balawi A, Greenland T. Seventeen years of surgical treatment of thymoma: Factors influencing survival. Eur J Cardiothorac Surg. 1991;5:124-31.
7. Su-Jin Park MD, et al. Thymolipoma in a 13-year-old Korean girl. Korean Journal of Pediatrics. 2010;53:1. DOI: 10.3345/kjp.2010.53.1.103
8. Wang Y, Sun Y, Zhang J, et al. Diagnosis, treatment and prognosis of thymoma: An analysis of 116 cases. Chin Med J. 2003;116(8):1187-90.
9. Roque C, Rodríguez P, Quintero C, Santana N, Hussein M, Freixinet J. Giant

- thymolipoma [Article in Spanish]. Arch Bronconeumol. 2005;41(7):402-3.
10. Scully NM. Lipothymoma with cystic lymphangioma. Am Surg. 1960;26: 400-4.
 11. Rosai J. Ackerman's surgical pathology. 8th ed. New York: Mosby. 1996;63,873-7.
 12. Hsu Shong Yeh, et al. Computed tomography and Sonography of thymolipoma. AJR. 1983;149:1131-1133.
 13. Gamanagatti S, Sharma R, Hatimota P, Guleria R, Arvind S. Giant thymolipoma. AJR Am J Roentgenol. 2005;185:283-4.
 14. Astasiadis P, Ratnatunga C. The thymus gland: diagnosis and surgical management. Berlin, Germany: Springer-Verlag; 2007.
 15. Ackman JB, et al. MRI of the thymus. AJR Am J Roentgenol. 2011;197:W15–W20. DOI: 10.2214/AJR.10.4703.
 16. Sasaka K, Kurihara Y, Nakajima Y, et al. Spontaneous rupture: a complication of benign mature teratomas of the mediastinum. AmJ. Roentgenol. 1998;170:323-8.
 17. Scott C. Gaerte, MD, Cristopher A. Meyer, MD. Helen T. WinerMuram, MD, Robert D. Tarver, MD, Dewey J. Conces, Jr, MD. Fat-containing Lesions of the Chest. Radiographics; 2002.

© 2015 Ramachandran et al.; This is an Open Access article distributed under the terms of the Creative Commons Attribution License (<http://creativecommons.org/licenses/by/4.0>), which permits unrestricted use, distribution, and reproduction in any medium, provided the original work is properly cited.

Peer-review history:
The peer review history for this paper can be accessed here:
<http://sciencedomain.org/review-history/9978>